Cyanotic Congenital Heart Disease

Professor Yiu-fai Cheung
MD, FRCP

Division of Paediatric Cardiology
Department of Paediatrics and Adolescent Medicine
The University of Hong Kong

Clinical Approach to Cyanosis in the Newborn

Case Scenario

- a male baby presents at 6 hours after birth with purple lips and perioral bluish discoloration during bottle-feeding and crying
- para 1, born full term by normal spontaneous delivery, birth weight 3.2 kg
- unremarkable antenatal and perinatal history
- appeared well otherwise
- no shortness of breath and no signs of respiratory distress
- no significant cardiac murmur

Cyanosis

- central *vs* peripheral cyanosis
- apparent in infants and children with 3-5 g/dL of reduced haemoglobin (note the confounding influence of anaemia or polycythaemia)
- ‘traumatic’ cyanosis

Causes of Central Cyanosis

- Cyanotic congenital heart disease
- Respiratory tract disease
  - airway obstruction
  - pulmonary parenchymal disease

Causes of Central Cyanosis

- Central nervous system (less common)
  - hypoventilation

    brain damage

    drug effect

- Congenital methaemoglobinaemia (rare)

Cardiac vs Respiratory

- factors predisposing to respiratory disease
- respiratory distress
- chest radiography
- hyperoxic test / nitrogen washout test (no longer performed nowadays)
  - >90% for >10 min

    normal : PaO2 > 50 kPa

    lung disease : PaO2 > 15 kPa

    cyanotic heart disease : slight increase in PaO2 (<1.5 kPa) or remains unchanged

Cardiac Origins of Central Cyanosis

- Pathophysiology
  - systemic venous blood bypassing the lung
    right-to-left shunts
    transposition haemodynamics
  - reduced pulmonary flow (in the majority)
    pulmonary outflow obstruction
    pulmonary atresia
  - common-mixing conditions
    atrial, ventricular, arterial levels

Categories of Cyanosis Congenital Heart Disease

(I) Right-to-Left Shunts with RV Outflow Obstruction

- tetralogy of Fallot
- tetralogy of Fallot with pulmonary atresia (PA with VSD)
- pulmonary atresia with intact ventricular septum

Tetralogy of Fallot

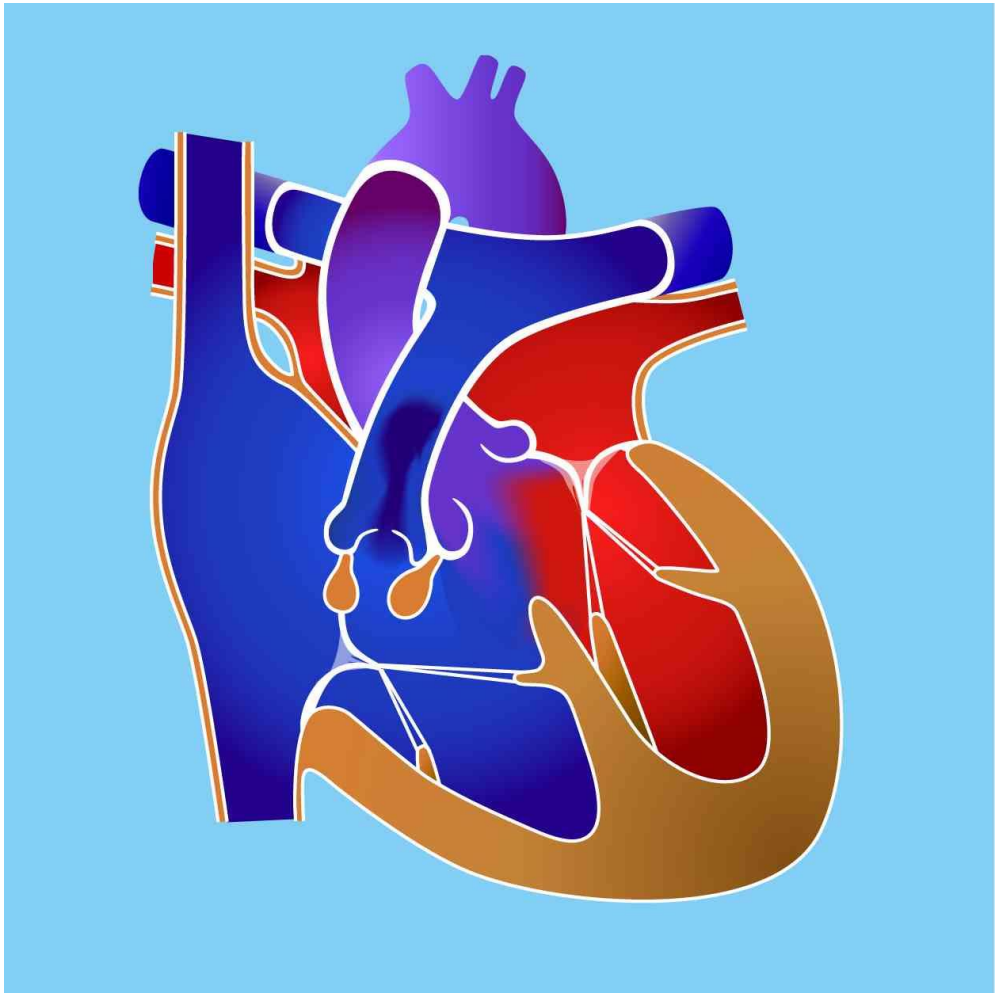

Tetralogy of Fallot

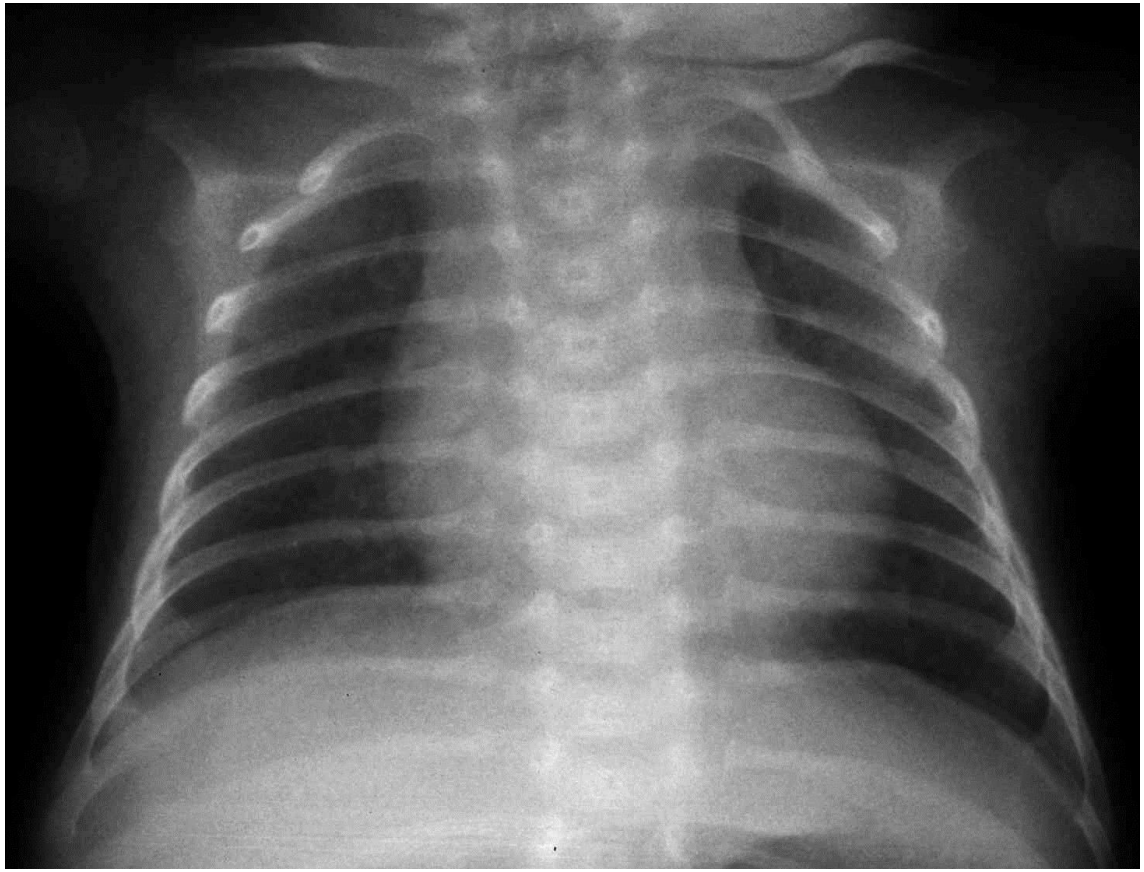

Boot-shaped heart

Oligaemic lung fields

Tetralogy of Fallot

Hypercyanotic spell

Tetralogy of Fallot

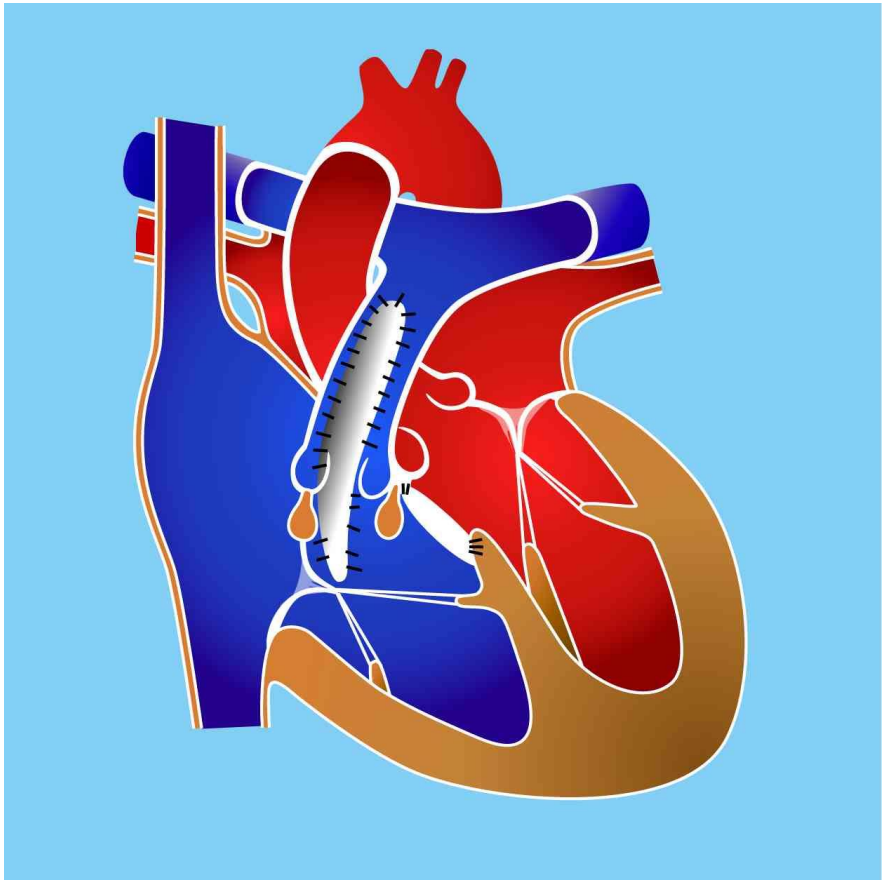

total surgical correction at about 6 to 12 months of age

Pulmonary Atresia With VSD (tetralogy of Fallot with pulmonary atresia)

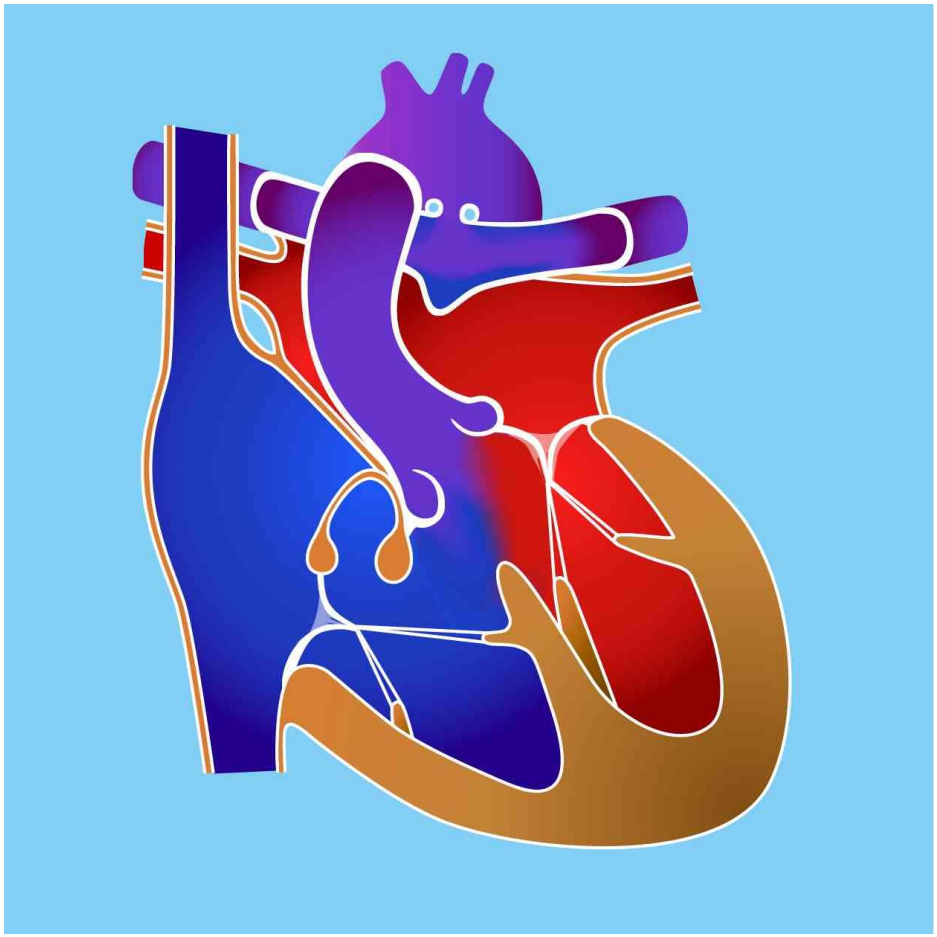

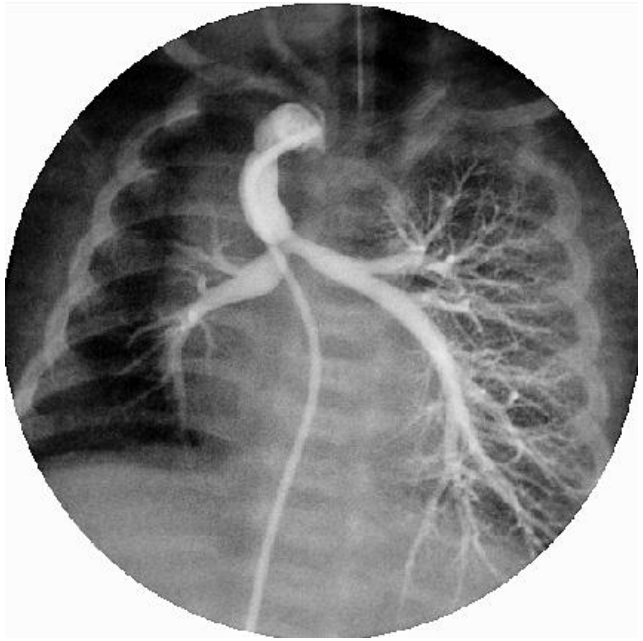

Concept of ‘ductal-dependent *pulmonary* circulation’

Prostaglandin E1 /E2

Pulmonary Atresia With VSD (tetralogy of Fallot with pulmonary atresia)

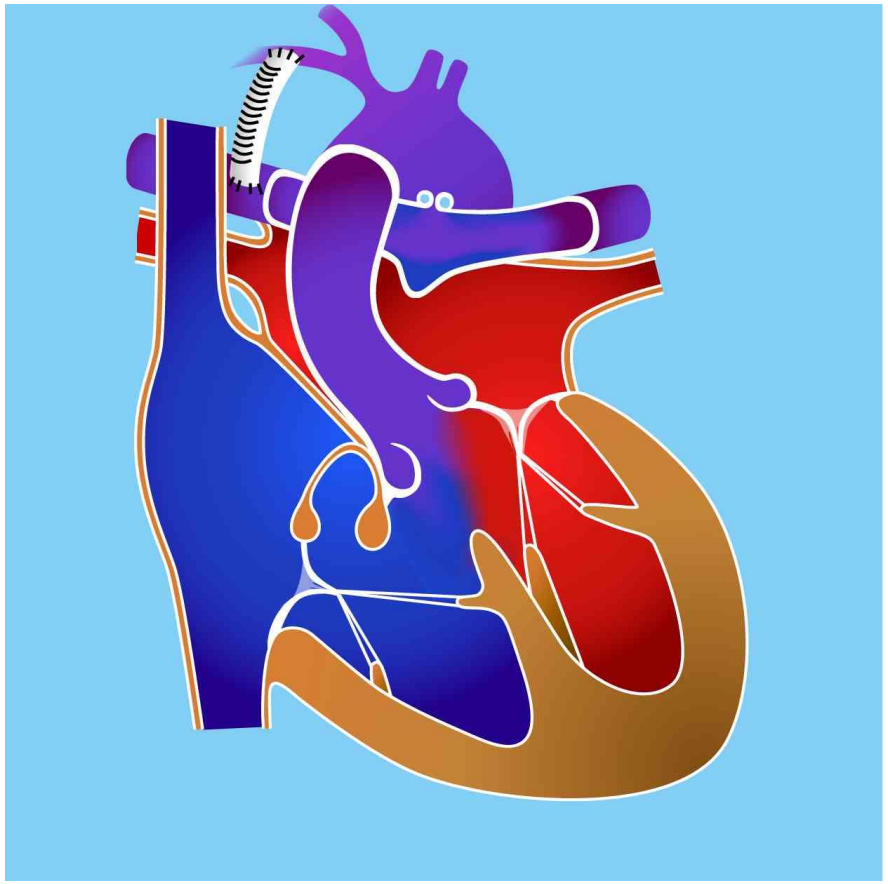

modified Blalock-Taussig shunt

surgical palliation by systemic-pulmonary arterial shunt (e.g. modified Blalock-Taussig shunt)

Pulmonary Atresia With VSD (tetralogy of Fallot with pulmonary atresia)

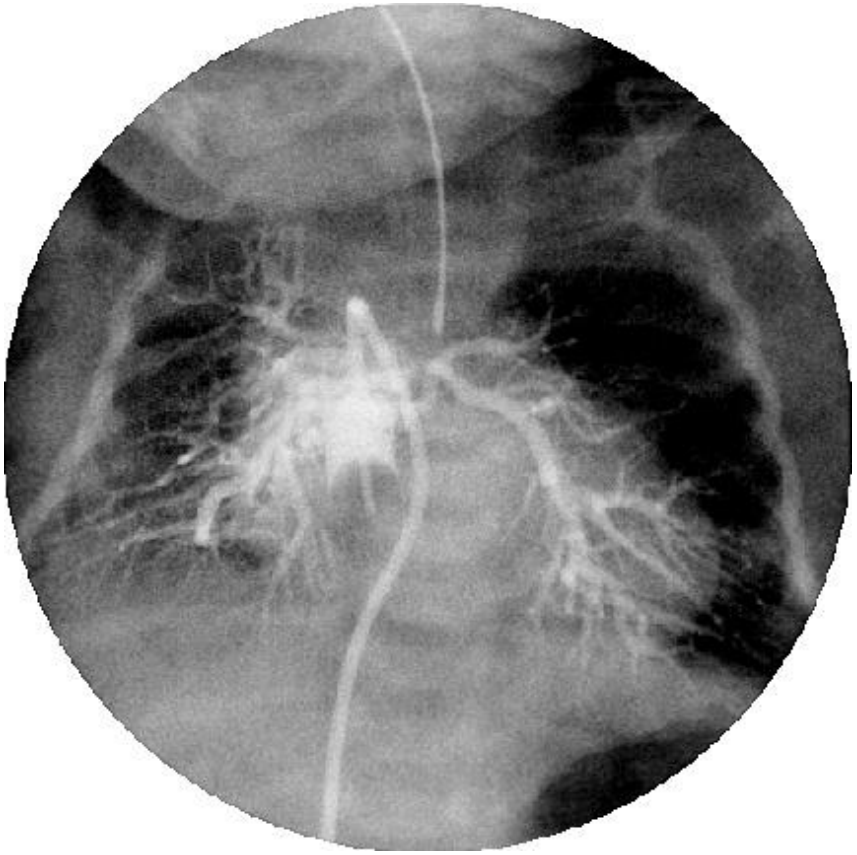



Unifocalization of aortopulmonary collaterals

Pulmonary Atresia With VSD (tetralogy of Fallot with pulmonary atresia)

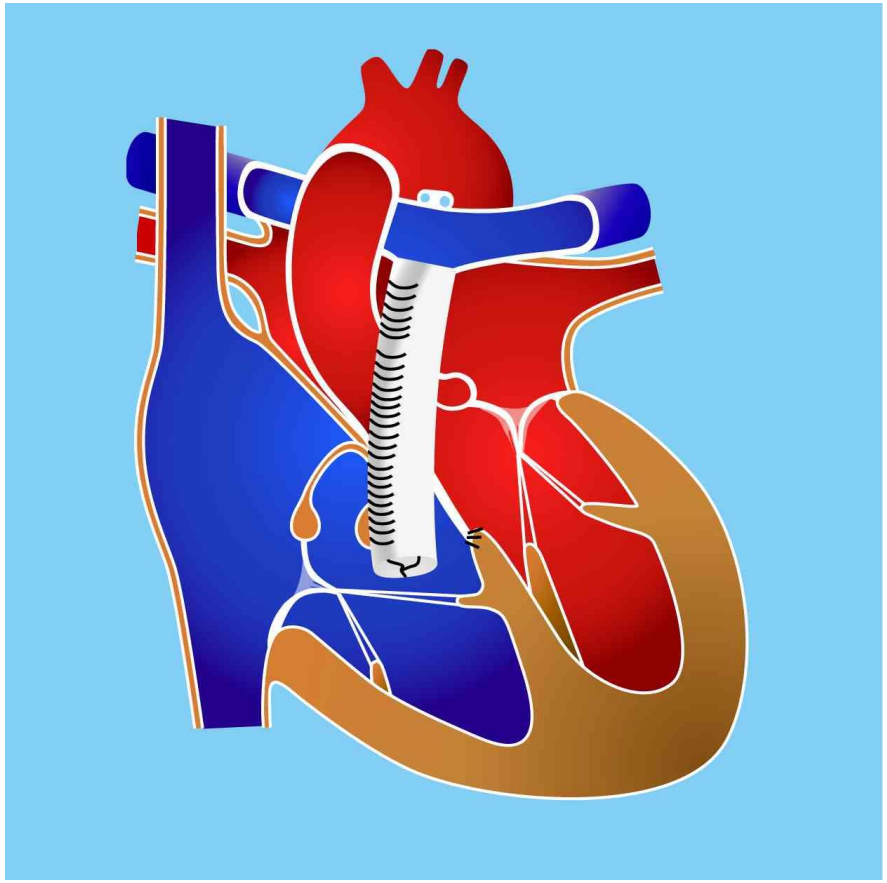

total surgical repair in infancy to early childhood

Pulmonary Atresia With Intact Ventricular Septum

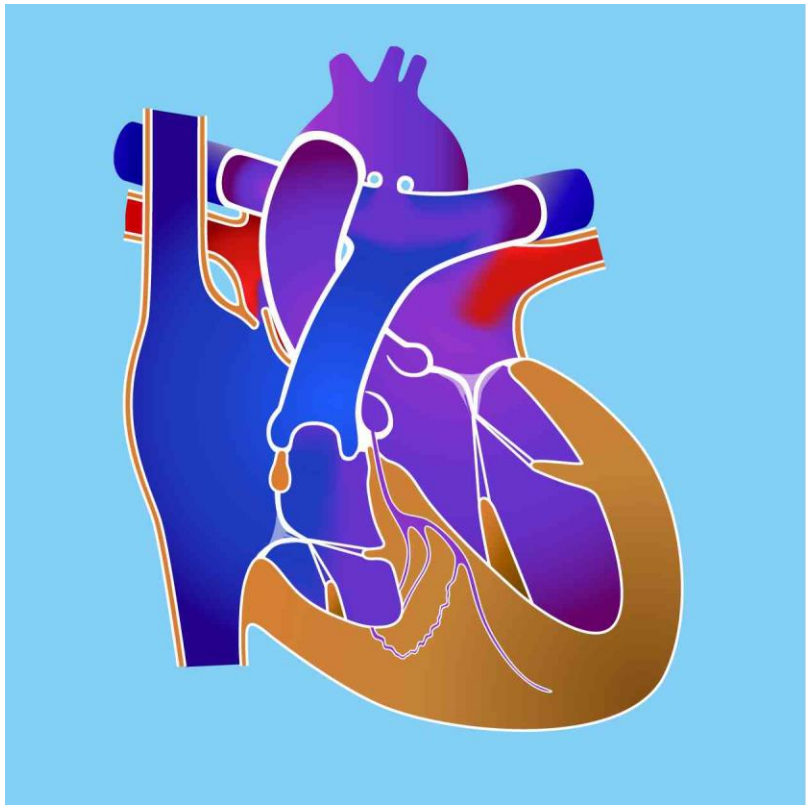

valve atresia

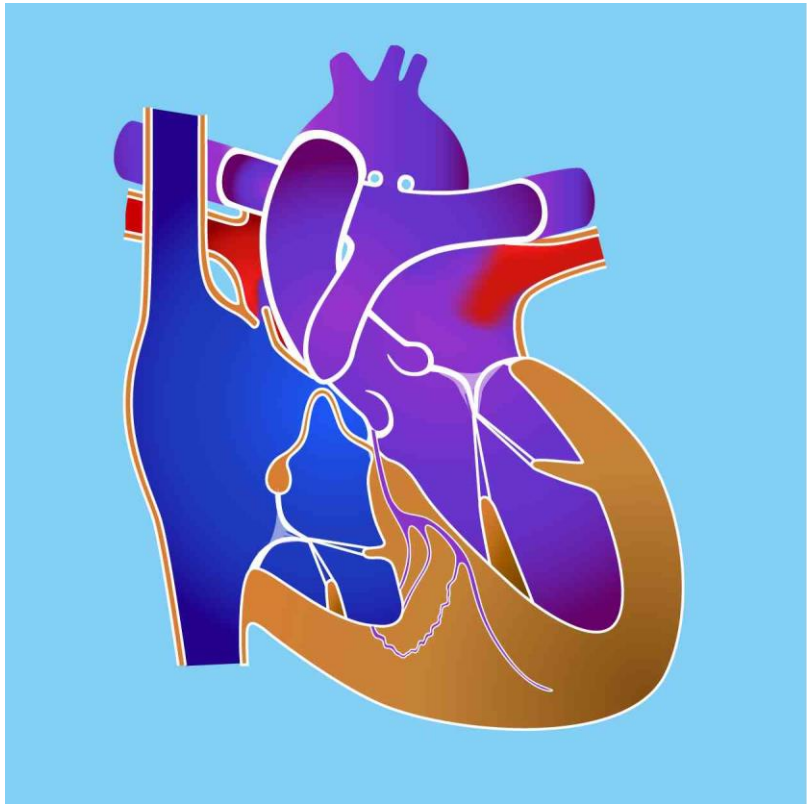

muscular atresia

Pulmonary Atresia With Intact Ventricular Septum

- duct-dependent pulmonary circulation
- initial stabilization with PGE1 / E2
- surgical palliation by systemic-to-pulmonary arterial shunt
- catheter or surgical opening of atretic pulmonary outflow

Pulmonary Atresia with Intact Ventricular Septum (PAIVS)

Radiofrequency-assisted pulmonary valvotomy

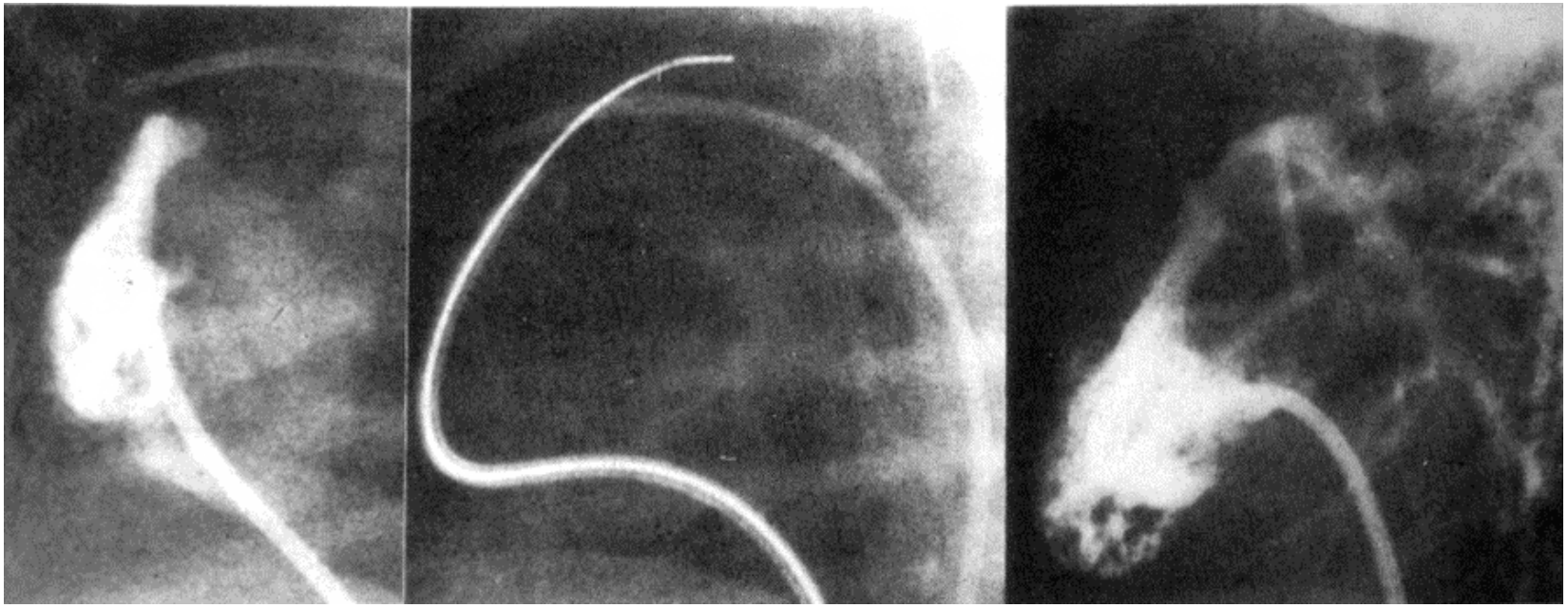

(II) Transposition of the Great Arteries

Transposition of Great Arteries

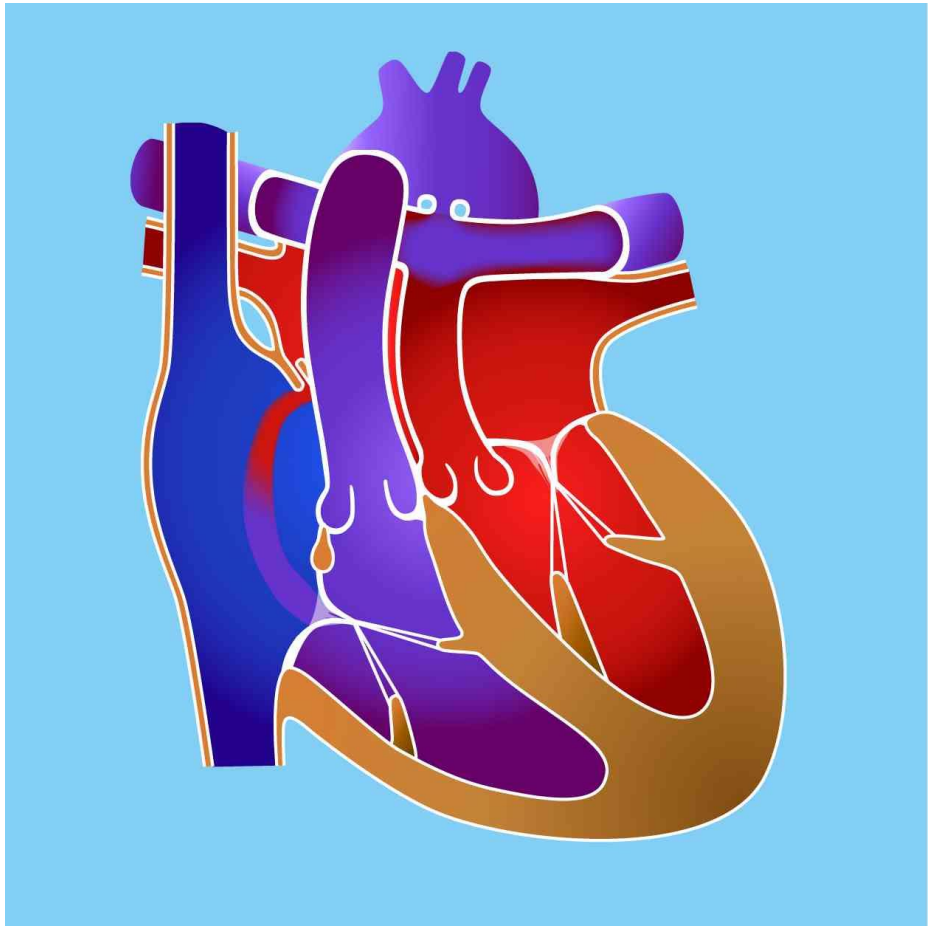

Parallel systemic and pulmonary circulation

High pulmonary blood flow

Transposition of Great Arteries

Sites for mixing

- arterial duct
- atrial septal defect

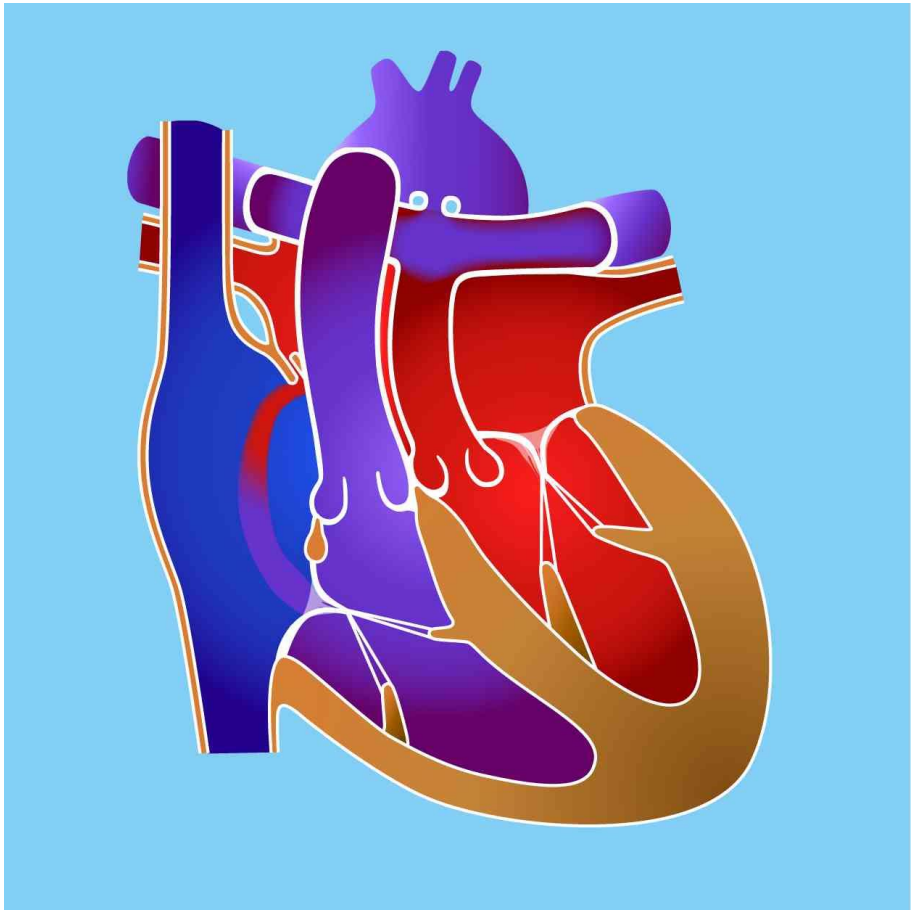

Transposition of Great Arteries

Balloon atrial septostomy

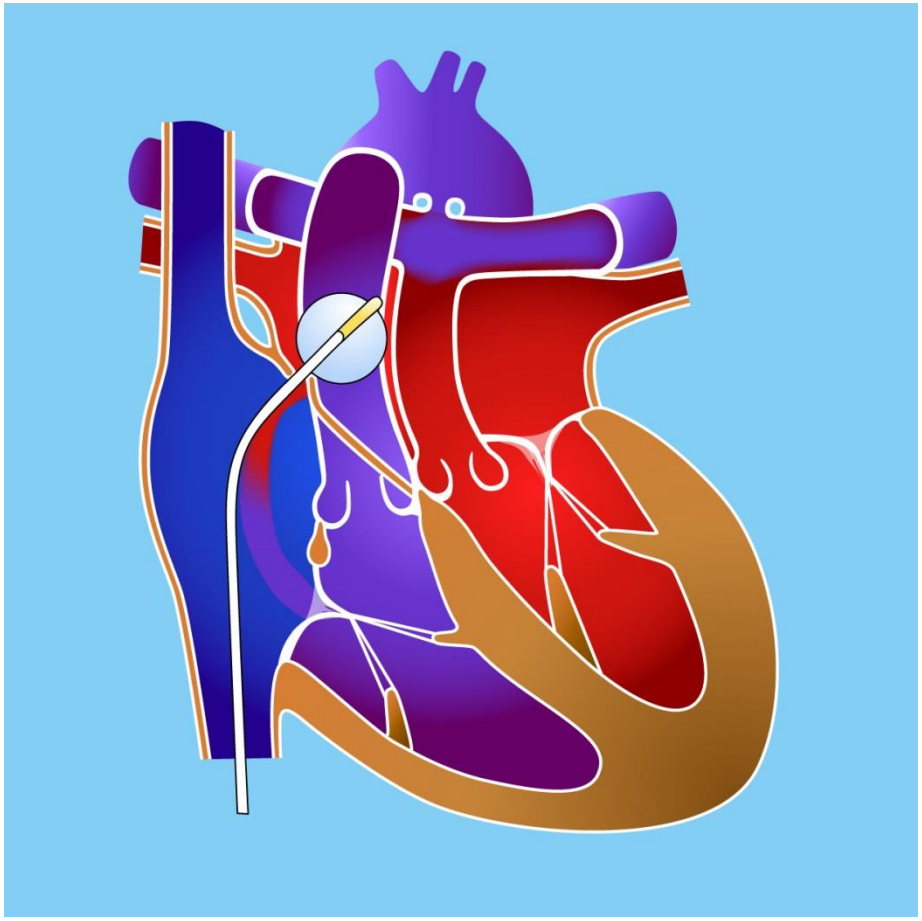

Transposition of Great Arteries

Balloon atrial septostomy

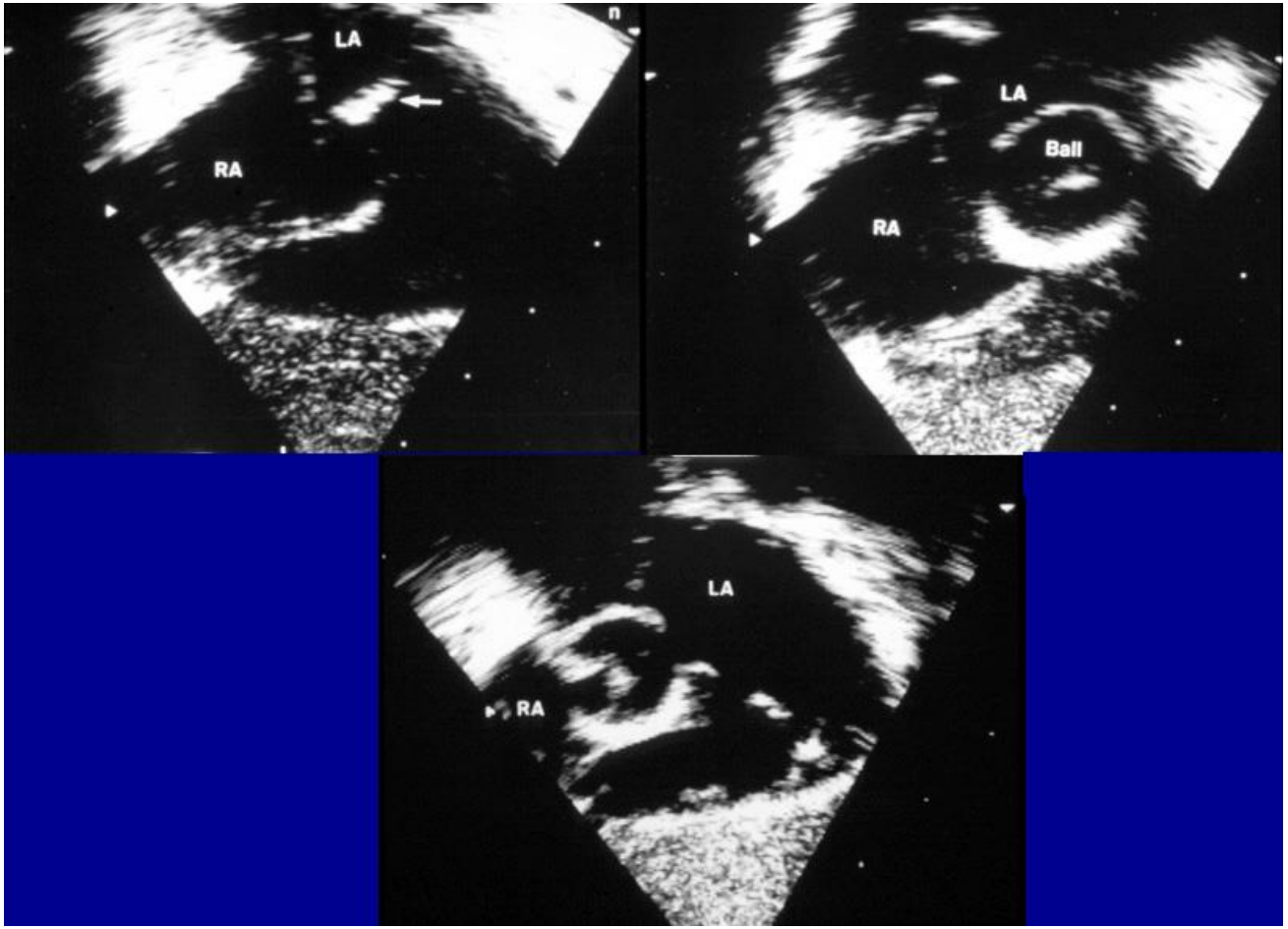

Transposition of Great Arteries

- Surgical options
  - arterial switch operation (anatomic correction, surgery of choice)
  - venous switch operation (physiologic correction, obsolete)

Transposition of Great Arteries

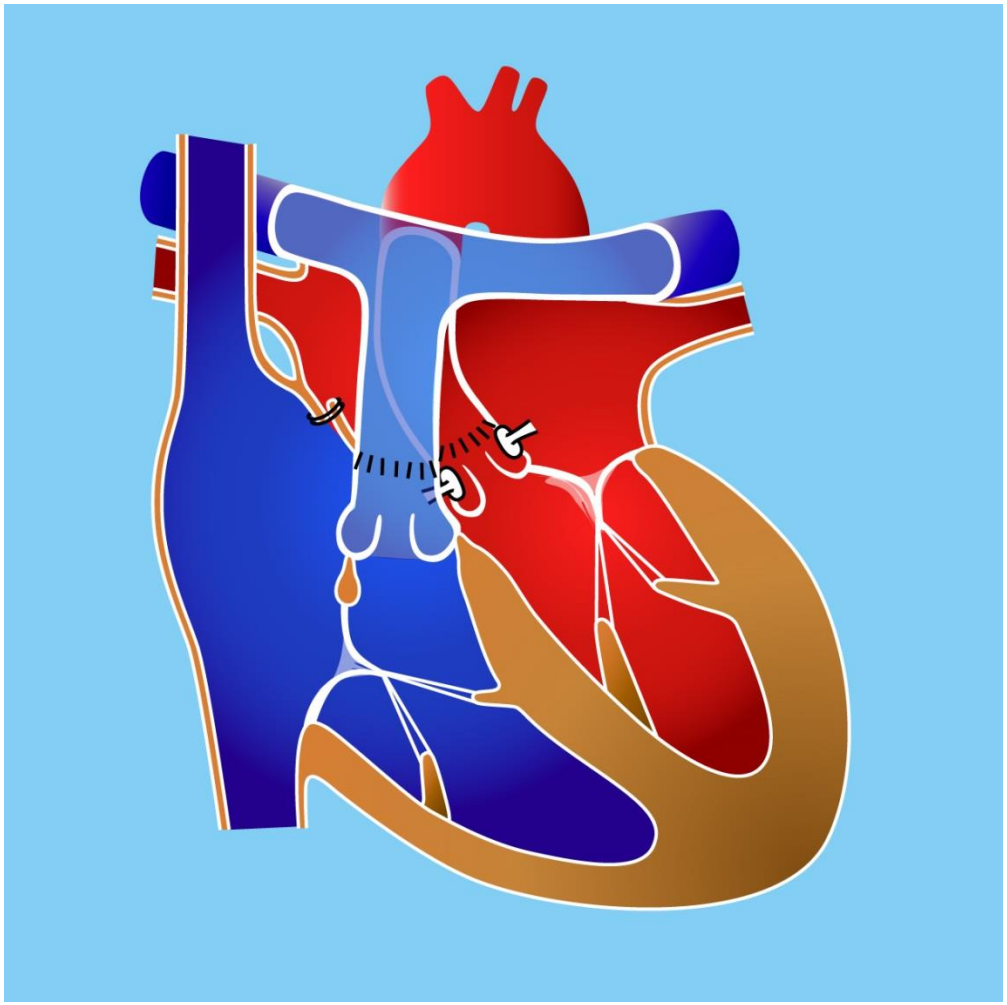

arterial switch operation performed in early neonatal period

Transposition of Great Arteries

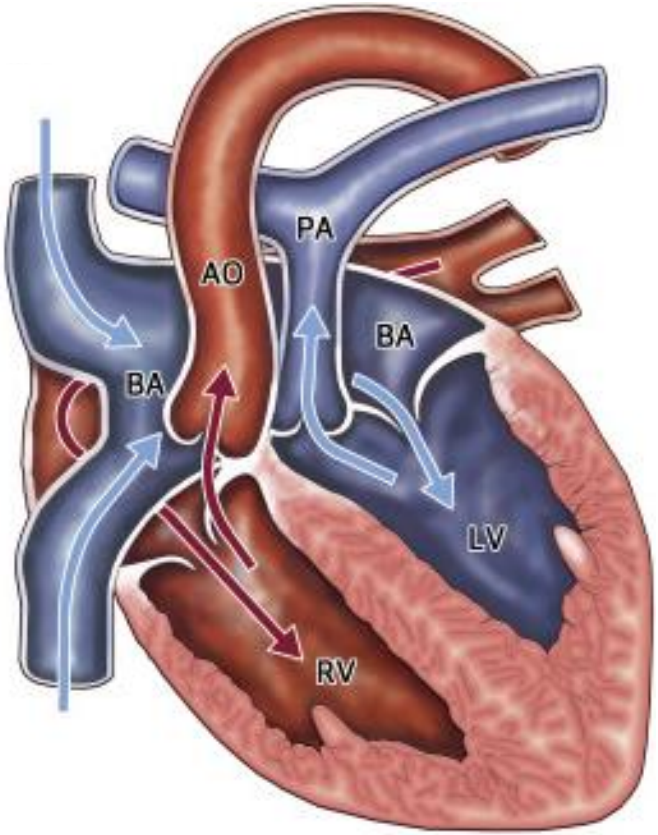

previous venous switch operations (Mustard / Senning operations)

Farooqi et al. JACC Heart Fail 2016

(III) Common Mixing Conditions

- arterial level → truncus arteriosus
- ventricular level → univentricular hearts
- atrial level → total anomalous pulmonary venous return

Truncus Arteriosus

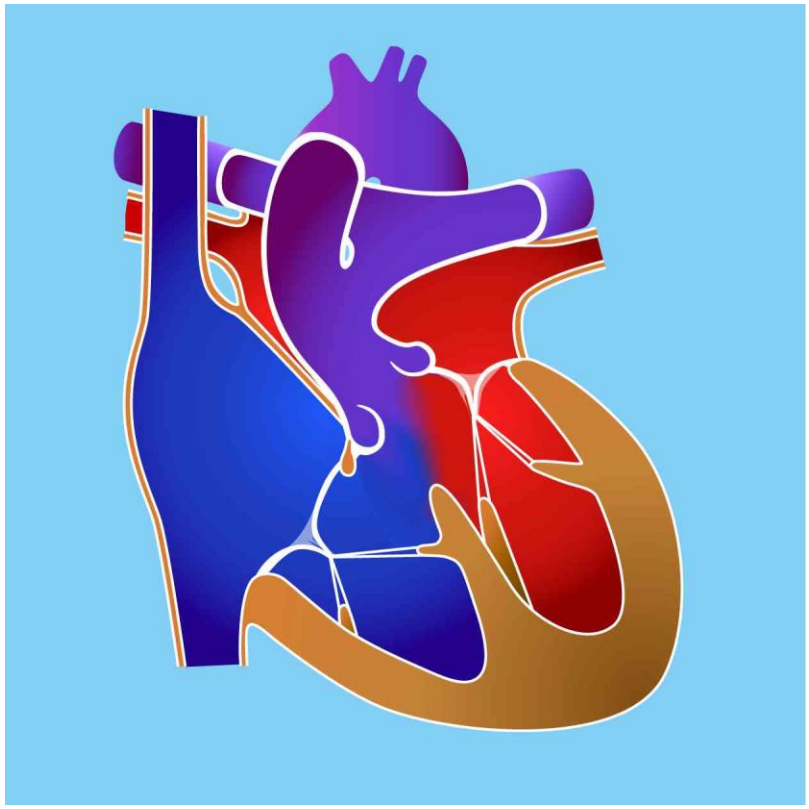

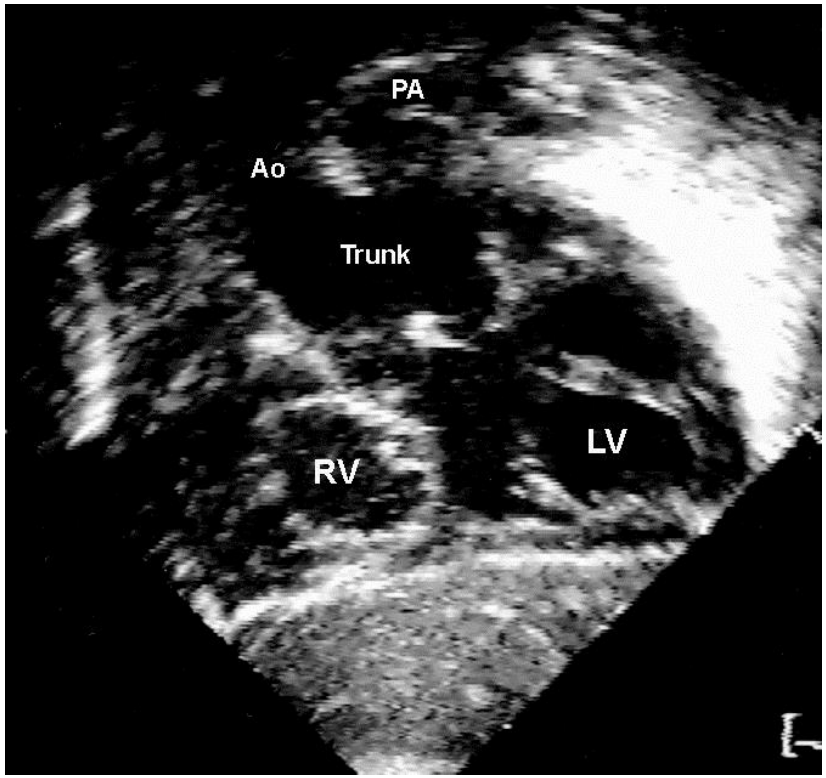

Truncus Arteriosus

- cyanosis usually mild
- heart failure symptoms predominate as pulmonary vascular resistance decreases after birth

Univentricular Hearts

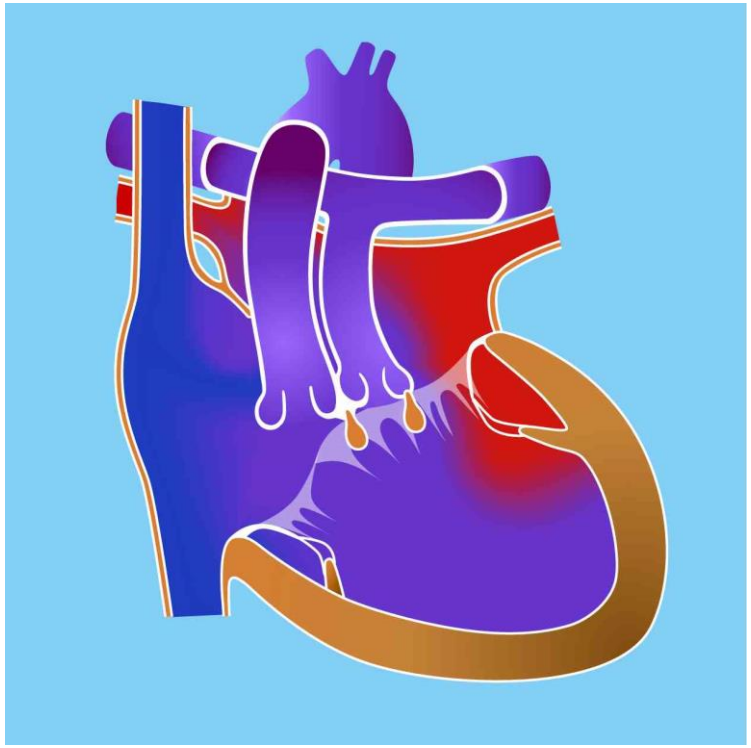

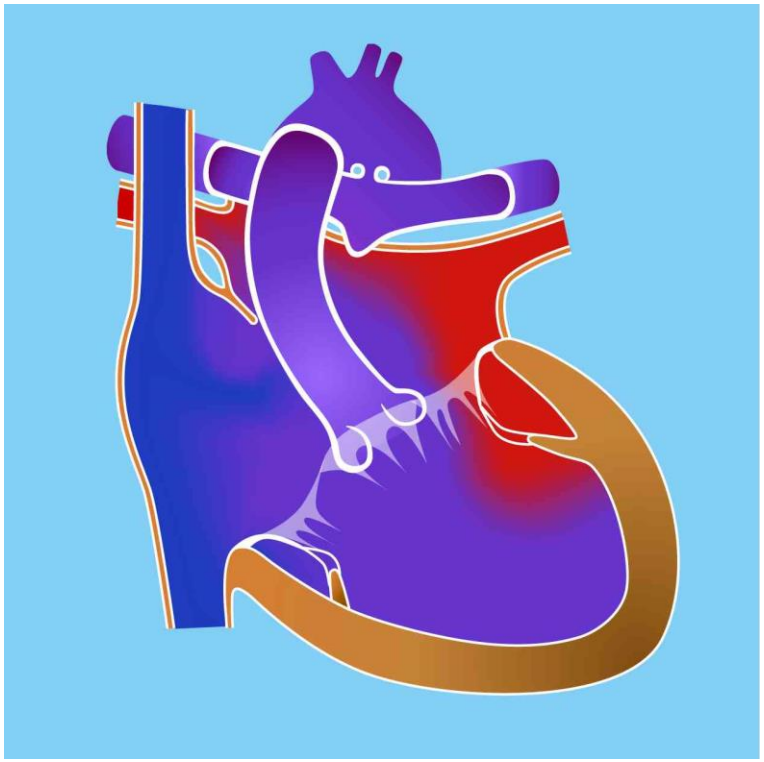

Univentricular Hearts

- Staged management
  - shunt insertion if pulmonary outflow obstruction is severe
  - Fontan-type procedure when older

Univentricular Hearts

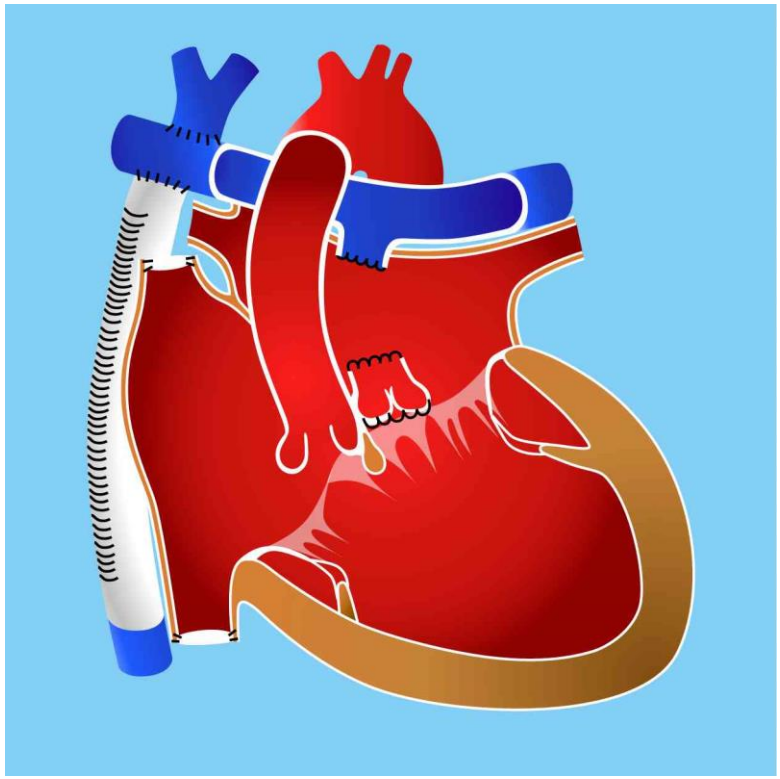

Fontan-type operation

Total Anomalous Pulmonary Venous Connection

Possible sites of drainage

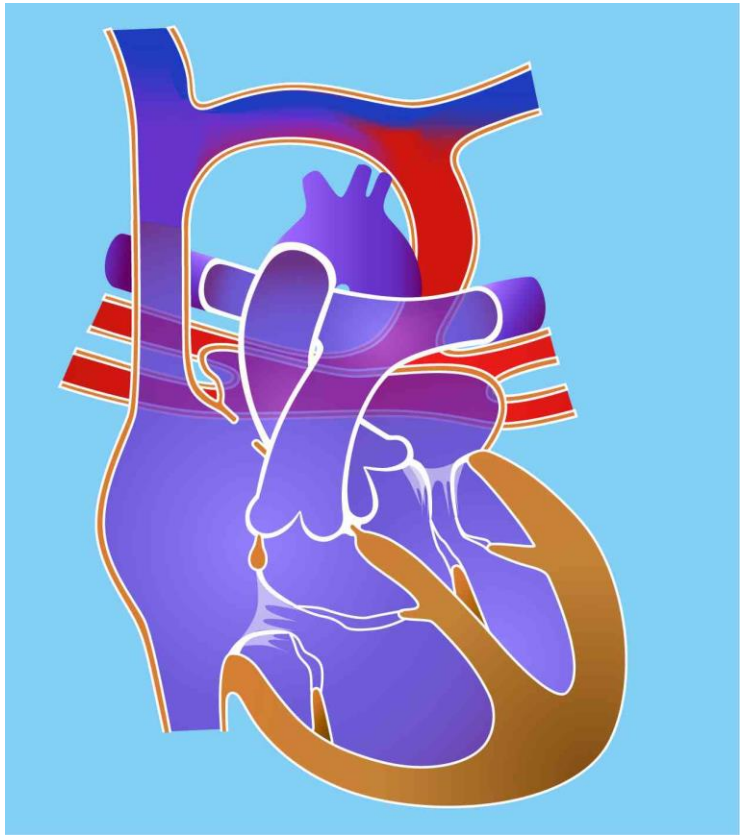

supracardiac

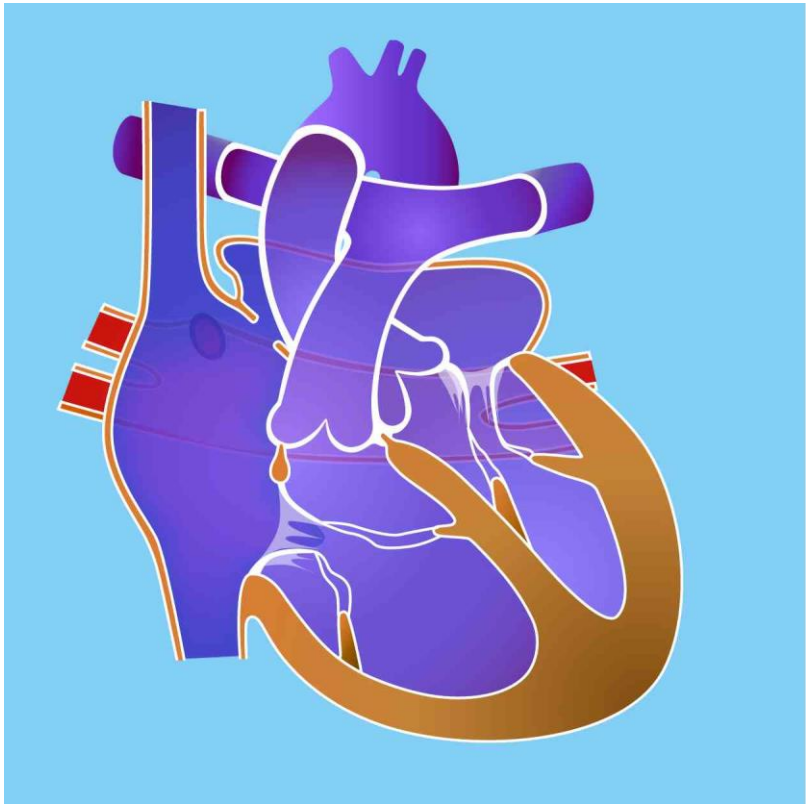

cardiac

Total Anomalous Pulmonary Venous Connection

Possible sites of drainage

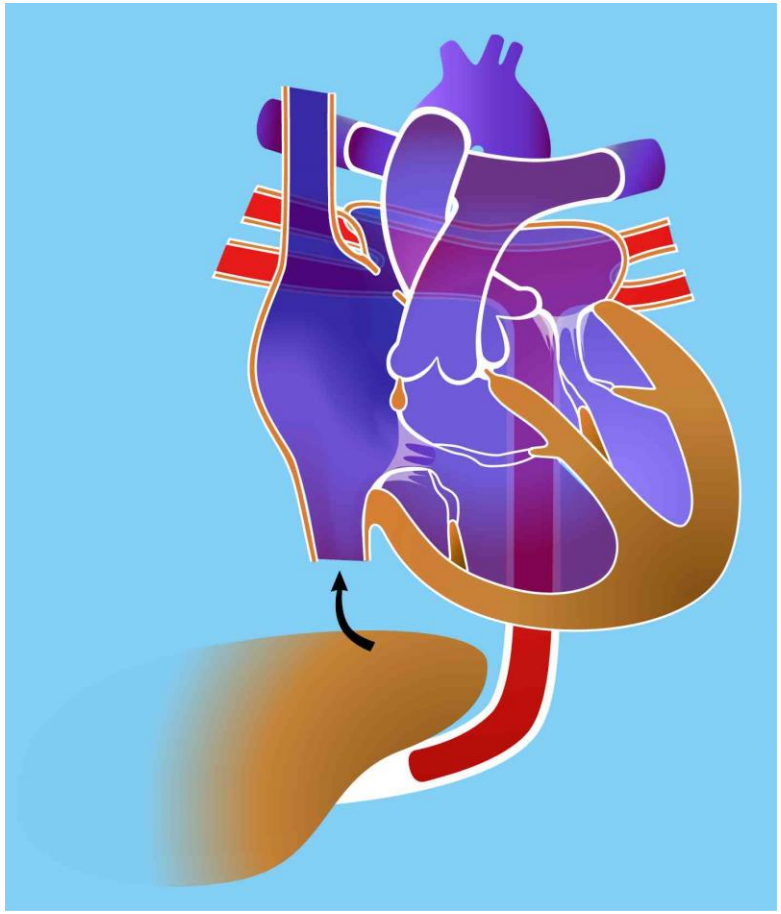

infracardiac

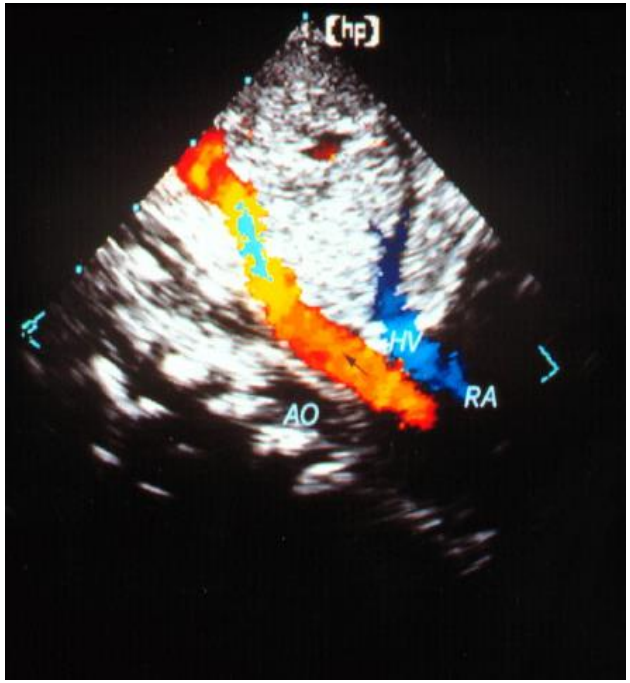

(IV) Ebstein Anomaly

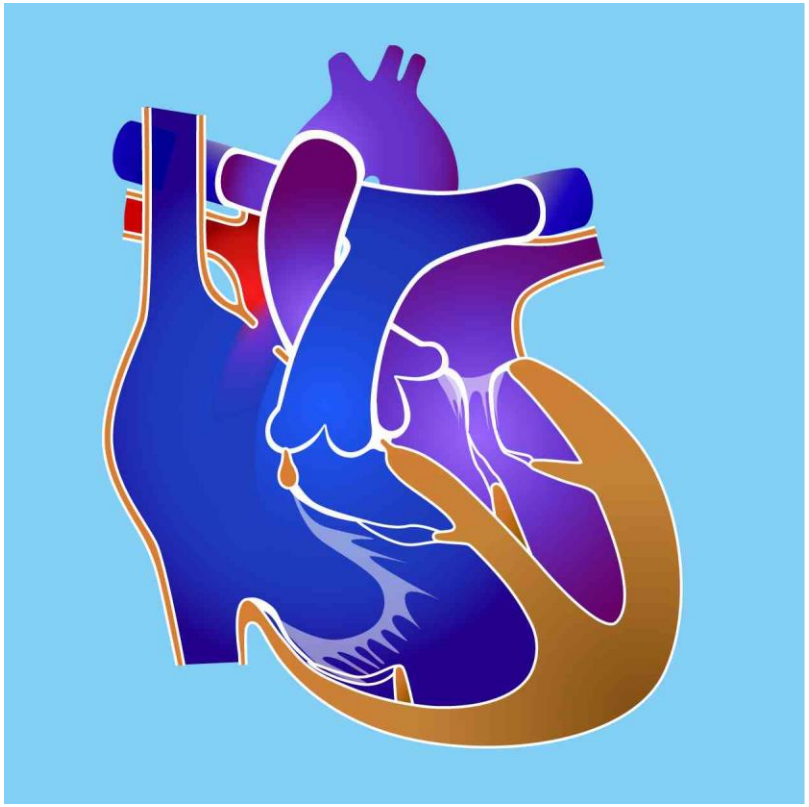

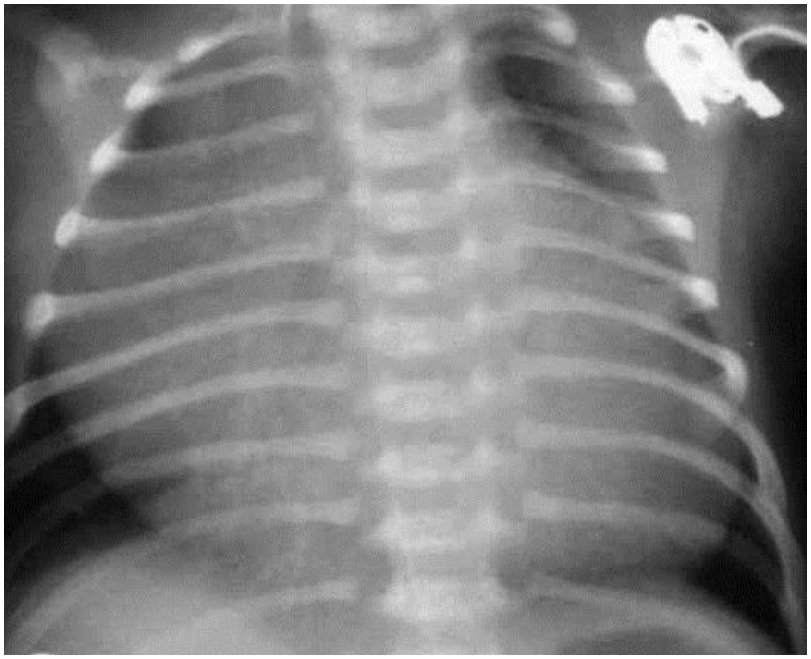

Overview

- Differentiation of cardiac from respiratory causes of cyanosis
- Cardiac origins of central cyanosis
- Categories and pathophysiologies of cyanotic congenital heart disease
- Duct-dependent pulmonary circulation
- Principles of management